

Multidisciplinary Approach for Oropharynx Cancer *(cont. from cover)*

State-of-the-art diagnostics

Most patients present at an advanced stage, when lymph node metastasis are visible. To help identify the site of the primary disease, PET/CT is used, often followed by a separate MRI to provide guidance for surgery. Endoscopies are also employed to locate the primary tumor, and ultrasound studies can locate cancer in the lymph nodes.

Technologically advanced treatment modalities

Because HPV-positive oropharynx disease responds so well to treatment, patients are offered many viable treatment options instead of or in addition to surgery.

Radiation. Radiotherapy is geared to cure early-stage oropharyngeal cancers, and it is most effective when the tumor burden is smaller. Advanced technology is used to customize the treatment based on the patient's functional status and general condition, as well as HPV or other tumor parameters. Radiation is delivered with curative intent, either alone or with chemotherapy, before surgery to shrink tumors or after surgery to kill any remaining cancer cells. The types of radiation used most often for oropharynx malignancy include external-beam radiation therapy, 3D conformal radiation therapy, intensity modulated radiation therapy and stereotactic radiosurgery.

Chemotherapy. Chemotherapy is also used for early oropharynx disease and can be used as an alternative to surgery, usually with radiotherapy as well, or as adjuvant therapy along with radiation. Neoadjuvant chemotherapy, sometimes with radiation, can be used to help shrink larger tumors or unresectable tumors. Frequently employed chemotherapy drugs include cisplatin, carboplatin, 5-fluorouracil, paclitaxel and docetaxel. In addition, newer targeting agents such as cetuximab and others are also used.

Combined modality treatment. Stony Brook's team determines the most suitable treatment based on a patient's need and in most cases highly recommends combined modality treatment to ensure the best functional outcome and cancer cure. In many oropharyngeal cancers, chemoradiation is administered concomitantly. This approach is also applicable for those who are not surgical candidates or whose tumors are large.

On the frontline for early detection

Primary care physicians — and dentists — are well positioned to spot early signs of oropharynx malignancy, which often manifests as a unilateral neck mass, and refer patients for evaluation and treatment. Practitioners are also encouraged to recommend that all girls and boys ages 11 and up start the HPV vaccination series to help prevent HPV-caused cancers in the future.

Contact Information

Stony Brook University Cancer Center
3 Edmund D. Pellegrino Road
Stony Brook, NY 11794-9452
(631) 638-1000

Radiation Oncology
(631) 444-2200/444-2210

Medical Oncology
(631) 638-1000

Stony Brook Cancer Today

Editor-in-Chief
Samuel Ryu, MD
samuel.ryu@stonybrookmedicine.edu

Correspondence to:
joan.garvey@stonybrookmedicine.edu
Communications Specialist

Produced by:
Office of Communications
Stony Brook Medicine



stonybrookmedicine.edu

Stony Brook University/SUNY is an affirmative action, equal opportunity educator and employer. 16051809H ©2016

Expertise Essential for Cancers of the Head and Neck Region

Multidisciplinary Approach for Oropharynx Cancer

Over the past couple of decades, while the incidence of most head and neck cancers has been falling, oropharynx cancer in the U.S. has reached epidemic rates, with a 225 percent increase between 1988 and 2004 and continued increases to date. But the oropharynx cancer that's so widespread today is different from the classic oropharynx malignancy seen in people who smoked or drank heavily. Now the most prevalent form — currently three out of four cases — is human papillomavirus-positive (HPV+) oropharynx squamous cell carcinoma (OPSCC).

Both men and women can get HPV-positive oropharynx cancers, though more males in their 50s, 60s or 70s are seen. Most do not have a history of smoking or alcohol abuse, and there is sometimes an association with having had multiple sexual partners. Patients were likely infected many years ago with HPV through sexual activity. The virus can remain latent for decades and then, for some people, eventually lead to HPV+ cancer of the oropharynx, which includes the tonsils and base of the tongue.

"Unfortunately there's no screening test like the pap smear for HPV-positive oropharynx cancer," explained Lukasz Czerwonka, MD,

head and neck cancer surgeon. "With HPV infection of the oropharynx, the initial tumor is often too tiny to see, so the cancer isn't caught until it's metastasized."

Here are some facts about this disease:

- HPV-positive oropharynx cancer is so widespread that it is predicted to outnumber cervical cancer from HPV by the year 2020.
- Patients with HPV-positive OPSCC — even those who present with more advanced disease — experience significantly better outcomes than patients with HPV-negative OPSCC.
- The cure rate for HPV-related oral cancer is close to 90 percent.
- Once diagnosed, optimal results are obtained through multidisciplinary care by evaluating and combining surgery, radiation and chemotherapy, which are tailored to the tumor stage and the patient's functional status.

A thriving robotic program

Surgery is often the first line of treatment for oropharynx disease, and at Stony Brook, 90 percent or more of HPV+ OPSCC surgeries are trans-oral robotic-assisted procedures. These can allow complete and more precise removal of tumors with fewer side effects, possibly fewer or no adjuvant therapies, and shorter or no hospital stays. If the tumor is too large to be resected

completely with robotic-assisted surgery, sometimes a minimally invasive technique that combines robotic-assisted and conventional surgery may be used.

Robotic-assisted procedures give the surgeons access to areas they normally can't reach without major trauma. For example, to visualize the base of the tongue and resect a tumor, a surgeon using a conventional open technique has to split the lip and mandible, which then need to be repaired with major surgery. Using a robotic-assisted approach, the surgeon can reach the tumor, visualize it under very high magnification and resect it with very close margins.

For patients whose cancers are not resectable by robotic-assisted surgery, conventional open surgeries with free-flap reconstructions are used.

"Robotic-assisted surgery has really revolutionized the treatment of oropharynx carcinoma. Tumors that used to be very debilitating to remove can now be resected almost entirely between the teeth, often with no external incisions and less trauma to other structures."

— Ghassan Samara, MD
Team Leader, Head and Neck, and Thyroid Oncology Management Team

(cont. on back cover)

IN THIS ISSUE

Multidisciplinary Approach for Oropharynx Cancer

Advances in the Treatment of Head and Neck, and Thyroid Cancers

Multiple Research Studies Provide Insights

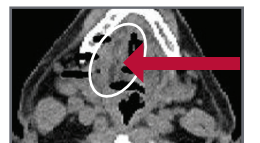Case Study: Squamous Cell Carcinoma

(2015) Evaluation and biopsy: Positive for squamous cell carcinoma; PET/CT scan revealed a tongue mass and two right level II lymph nodes noted with hypermetabolic activity. Robotic-assisted glossectomy confirmed squamous cell carcinoma on the base of the tongue.

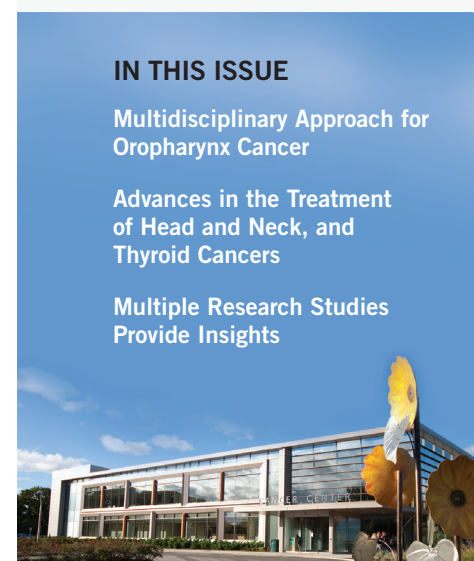
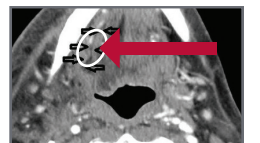
Treatment: Right modified radical neck dissection, 2/35 lymph nodes positive for metastatic cancer, invading skeletal muscle. Lymphovascular invasion: T3N2b. Weekly chemotherapy with radiation post-operatively.

(2016) Post-treatment: Four endoscopic dilations of esophageal stricture. Considerable improvement in dysphagia; able to consume solids. Ten months after completion of chemotherapy/radiation, feeding tube removed. Patient is maintaining a normal weight, improving articulation and currently cancer free.

Pre-treatment:
CT scan of carcinoma



Post-treatment:
CT scan of area





Message From the Deputy Director

Samuel Ryu, MD
Deputy Director, Clinical Affairs
Stony Brook University Cancer Center

Advancements in cancer care are being realized at an unprecedented speed, for which my colleagues and I are grateful. Evolving technology and the innovative use of existing ones are improving diagnostics and treatment.

At Stony Brook, we have just added the Varian® Edge™ in the Department of Radiation Oncology – the first on Long Island. Why did we acquire it? The Edge radiosurgery system represents an evolution in the way advanced radiosurgery is delivered. This system tracks the patient's tumor in real time, precisely calculates patient movement in all six degrees of freedom and monitors respiratory motion. All of this benefits our patients.

We are also progressing on the leadership front. Yusuf Hannun, MD, Director, Stony Brook University Cancer Center, announced the appointment of Patricia Thompson, PhD, to the position of Deputy Director for Research at the Cancer Center. In her new role, Dr. Thompson will oversee all cancer research activities.

Dr. Thompson is a nationally recognized researcher focusing on the discovery and validation of biomarkers to identify individuals at greatest risk for cancer recurrence. She leads a nationally prominent research program that concentrates on the evolution of molecular and cellular changes that occur during the development of colorectal and breast cancer. Her overarching goal moving forward is to assist all cancer research teams in the development of more precise and effective targeted therapies. We look forward to her visionary and tenacious leadership.

As always, I would like to extend a personal invitation to discuss any aspect of the Cancer Center with you. You can contact me at (631) 444-2200.

Did You Know?

One type of indolent, non-progressing thyroid cancer has been reclassified as a non-cancer, to reduce over diagnosis, overly aggressive treatment and patient anxiety. Now known as noninvasive follicular thyroid neoplasm with papillary-like nuclear features (NIFTP), its recommended treatment is lobectomy only.

Advances in the Treatment of Head and Neck, and Thyroid Cancers

At Stony Brook University Cancer Center, the multidisciplinary Head and Neck, and Thyroid Oncology Management Team delivers the full spectrum of state-of-the-art diagnostic and treatment modalities for people with malignancies of the thyroid, salivary glands, skull base, hypopharynx, larynx, nasal cavity, oropharynx, oral cavity and sinuses.

Thyroid Cancer Diagnosis and Treatment Modalities

In 2016, an estimated 62,450 new cases of thyroid cancer will be diagnosed in the United States, according to the American Cancer Society. Though the mortality rate from thyroid cancer remains very low compared to most other cancers, 20 to 30 percent of patients will have persistent and recurrent disease.

Most thyroid cancers can be treated very successfully, thanks to early detection, though even malignancies caught in later stages generally respond well to treatment. For stages I and II papillary carcinomas (the most common type of thyroid cancer), the five-year relative survival rate is near 100 percent, and for stage III it is 93 percent.

Skilled surgical intervention

Surgery is almost always the first-choice treatment, and very often the only treatment

needed, for early-stage thyroid carcinoma. For locally advanced disease or metastatic disease, most patients need surgery along with adjuvant radiation or chemoradiation.

- Thyroidectomy is the most common surgical procedure for thyroid cancer. Resection can be total or partial.
- Selective neck dissection may also be done if needed to remove diseased nodes and to confirm or rule out metastasis.
- Hemithyroidectomy, also called lobectomy, is used to treat small malignancies that haven't spread beyond the one lobe of the thyroid or to confirm cancer if diagnostics have been inconclusive.
- Ultrasound-guided injections of alcohol into small malignancies can ablate lesions that weren't accessible in surgery.

At Stony Brook Cancer Center, thyroidectomies and hemithyroidectomies can be done with minimally invasive techniques using endoscopes through a neck incision that's less than five centimeters. ■

Advanced Radiation Therapy Modalities

Radiation therapies have become increasingly sophisticated, optimizing effectiveness while minimizing potential adverse reactions.

- Adjuvant radioactive iodine (RAI) may be used in patients whose cancer has spread beyond the thyroid gland to ablate remaining thyroid tissue and microscopic tumors.
- Dosages for RAI have been lowered, especially for lower risk neoplasms.
- Adjuvant external beam radiation therapy (EBRT) is often used after surgery for patients with locally advanced thyroid cancer to reduce the recurrent disease.
- Intensity-modulated radiation therapy (IMRT) uses a conformational beam that is shaped for a specific region and reaches the tumor from a variety of angles. It allows the delivery of very high doses of radiation to the cancer with reduced risk of injury to other parts of the neck and throat.

A new age in medical therapy

Current medical therapies are precision medicine, allowing for refined prognostication and therapeutic strategy.

- Modalities include chemotherapy, chemoradiation, targeted drug therapies and biologic therapies, and molecular profiling.
- Chemotherapy, administered as an infusion, injection or orally, is given to patients with advanced disease.
- Targeted drug therapies for advanced and metastatic disease can treat cancers that don't respond to or have stopped responding to RAI and other treatments.
- Biologic agents work with a patient's immune system to fight advanced cancers that don't respond to more traditional chemotherapy treatments.
- Molecular profiling exposes the pathogenesis of a patient's disease, allowing for better risk stratification, reduction in the number of unnecessary invasive procedures and better identification of aggressive malignancies that need to be treated aggressively. ■

Treatments for Salivary Gland Cancer

Salivary gland cancers affect about one per 100,000 people and comprise less than one percent of cancers in the U.S., according to the American Cancer Society.

If found early, salivary gland carcinoma has a high cure rate. The challenge in treating these cancers is preserving the function of the adjacent nerves, organs and tissues. Treatment can adversely affect appearance, speech, eating and breathing, all of which can diminish quality of life.

Precision surgery

The first course of treatment for all patients diagnosed with a salivary gland cancer is surgery with the goal of removing as much of the tumor as possible and leaving clean margins.

Parotidectomy (removal of the entire parotid gland). For this surgery, the parotid gland — the most common site of salivary gland cancer — is accessed by an incision in front of the ear and extending down to the neck. If the cancer has grown into the facial nerve, the nerve will be removed and a nerve graft may be necessary to restore some facial muscles. Reconstructive surgery is needed after a total parotidectomy.

Superficial parotidectomy (removal of the one lobe of the parotid gland). Most parotid gland cancers occur in the superficial lobe, which is the outside of the parotid gland. If the cancer is confined to that area, a superficial parotidectomy may be performed. This usually spares the facial nerve and preserves normal facial movement.

Endoscopic surgery. Accessing and resecting the gland through an endoscope is less damaging to facial tissue than conventional surgery, but it can only be used in certain areas.

PHYSICIANS:

To discuss your patient's case, refer a patient or to learn more, call the Head and Neck, and Thyroid Oncology Team at (631) 444-4120.

PATIENTS:

To learn more or to make an appointment, call (631) 638-1000.

Neck dissection. The extent of the dissection is determined by how extensively the cancer has spread into the lymph nodes.

Cutting-edge radiation therapies

If a salivary gland cancer can't be surgically resected or if cancer cells remain after surgery, radiation therapy may be prescribed.

External-beam radiation therapy (EBRT) is used if the tumor has grown into soft tissue, spread to the lymph nodes, or as with parotid cancer, surrounds a nerve.

Intensity-modulated radiation therapy (IMRT), a form of EBRT, delivers higher doses of radiation from multiple angles while protecting nearby healthy cells.

Accelerated hyperfractionated radiation therapy delivers high doses twice a day over a shorter total length of time.

Proton beam therapy, also an external beam modality, uses high energy radiation to destroy salivary gland cancers located close to nerves.

Internal radiation therapy (brachytherapy) surgically implants pellets or rods containing radioactive materials in or close to the cancer.

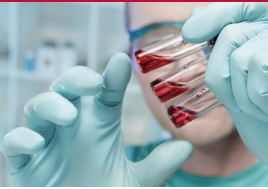Three-dimensional conformal radiation therapy (3D-CRT) uses MRI images to precisely map tumor locations. Radiation beams are shaped and aimed to hit the tumor from many different angles.

Chemotherapy

Chemotherapy is used for later-stage cancers that did not respond to surgery or radiation, or for patients with metastasized salivary gland cancers. It is not curative. Chemotherapy may also be used after or instead of surgery, alone or with radiation.

Several clinical trials are currently evaluating the efficacy of new drugs and drug combinations in treating salivary gland malignancies. ■

Focus On Clinical Trials and Research



Multiple Research Studies Provide Insights

To quantify selective practices and patient outcomes in Transoral Robotic Surgery (TORS) in New York State, a multidisciplinary team of researchers at Stony Brook University Cancer Center analyzed data from the NY Statewide Planning and Research Collaborative all-payer administrative database. The research was conducted in three parts with three distinct objectives.

Objective #1: Identify local practice patterns for the timing of neck dissection (ND) in relation to TORS
Conclusions: Concurrent procedures are most commonly practiced in New York State and are more cost-effective. However, the rate of staged procedures is increasing. Access to concurrent versus staged procedure does not depend on patient demographics or insurer status, but racial disparities exist in overall access to TORS.

Objective #2: Compare TORS outcomes of concurrent versus staged ND.
Conclusions: Concurrent and staged TORS and ND procedures are equally safe. Length of stay is shorter for concurrent procedures, although the overall cost and clinical benefits associated with this finding are unknown. It is reasonable to allow operator preference and patient factors to determine surgical logistics.

Objective #3: Discover the incidence and optimal timing of gastrostomy tube (GT) placement for patients undergoing TORS and ND.
Conclusions: One-fifth of 90-day readmissions in TORS and ND in NYS are related to impaired oral intake resulting in delayed GT. Patient risk factors combined with a complicated hospital course can identify patients benefiting from early GT, enhancing post-operative resource utilization.

These ongoing studies are funded through the Stony Brook Medicine Surgical Outcomes Analysis Research (SOAR) Collaborative.

PET/MRI vs. PET/CT for diagnostic accuracy

A research project to investigate the latest diagnostic methods for treating cancers of the head and neck region is underway. The Head and Neck, and Thyroid Oncology team is studying the benefits of using Positron Emission Tomography (PET) and Magnetic Resonance Imaging (MRI) versus the traditional PET and Computed Tomography (CT) scans to locate and diagnose cancers of the oral cavity, tonsil or base of the tongue. Malignancies in that region are difficult to detect because of the musculature surrounding the affected structures. An MRI provides significantly more information and is less affected by dental artifacts, thereby enhancing the ability to diagnose and plan treatments for these patients.